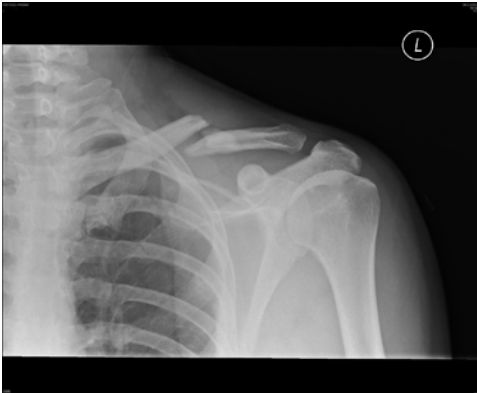


Medical Imaging and Science Hand In Assignment

Below you will find scenarios that require the use of one of the many examples of medical imaging. Your task will be to fill in the table below each scenario to help you understand the differences between each type of medical imaging. One website has been provided for each scenario. This website should only be a starting point; be sure you are double-checking the information you find on CREDIBLE websites.

Scenario #1: Billy's Bike Accident

Billy, an avid mountain biker, was out and about in the trails in Banff National Park. As some of you may know, these trails can get somewhat "steep". Billy, being the testosterone filled adolescent that he is, is not afraid of such tasks and does not hesitate in his attempt to conquer the mountainside. However, as most parents would have predicted, Billy suffers a gruesome fall and now cannot move his right arm. When the EMTs arrive, they take him into town for immediate medical assistance. It is here that the doctor on staff orders an x-ray for Billy's shoulder. The film below illustrates what the doctor found out from the x-ray.



Use your research skills to fill in the table below to help Billy understand why he had to wear that "ugly, heavy vest".

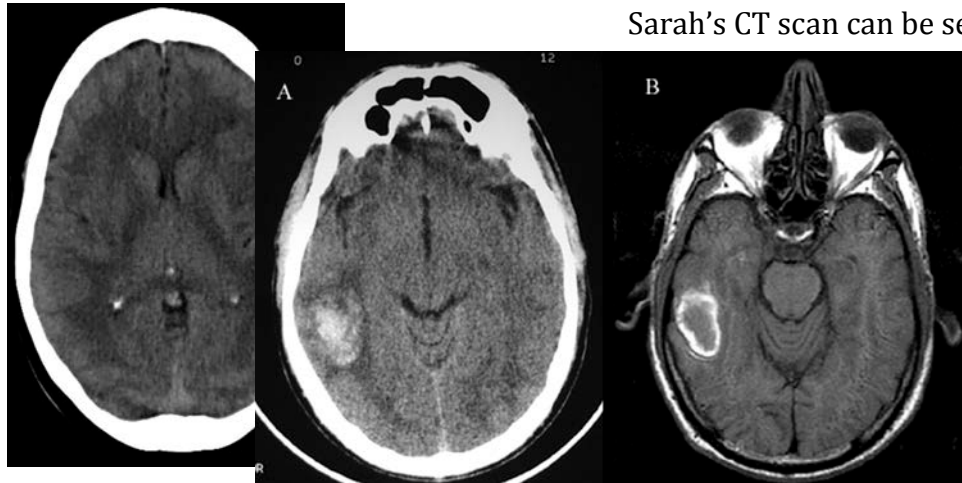
<http://www.medicalradiation.com/types-of-medical-imaging/imaging-using-x-rays/radiography-plain-x-rays/>

Complete Name	Why the doctor wanted an x-ray (ie. how the image is formed)	What types of structures can be viewed?

Scenario #2a: Sarah's Slip

Sarah loved being on the ice; the cantilever was her favorite spin to perform. However, Sarah had a new partner (Franco) and had not yet mastered the death spiral, which is what the judges wanted to see for the major points! Sarah and Franco worked very hard everyday to master the death spiral, but one day the toe of Sarah's skate caught on some debris on the ice and she lost her balance. Being that Sarah's head was so close to the ground during this spin, it is not a surprise that she banged her head and lost consciousness. As with any loss of consciousness, the ambulance was called. When Sarah did not regain consciousness, she was rushed to hospital where the emergency doctor ordered a CT scan for her cranium.

Below you will see a normal CT scan:



Sarah's CT scan can be seen below:

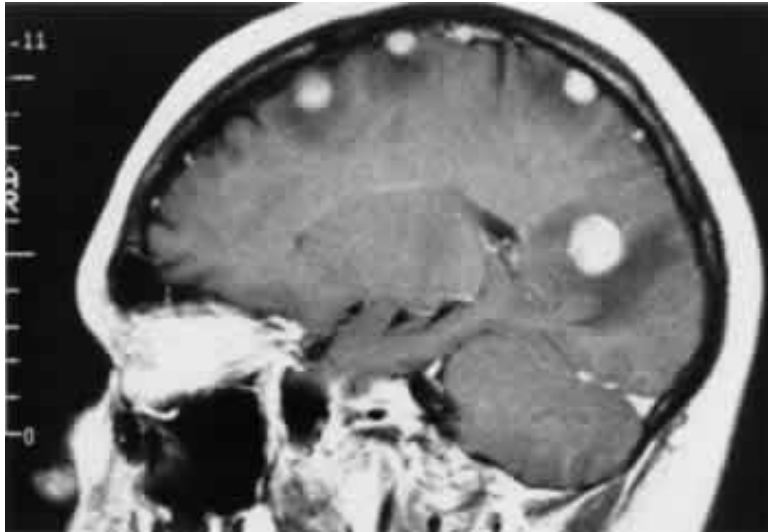
Use your research skills to fill in the table below to help Sarah's mom understand why they rushed Sarah in for a CT scan when they got to the hospital and why they wanted her consent.

<http://www.medicalradiation.com/types-of-medical-imaging/imaging-using-x-rays/computed-tomography-ct/>

Complete Name	Why the doctor wanted a CT (ie. how the image is formed)	Advantages of diagnostic test	Disadvantages of the diagnostic test

Scenario #2b: Sarah's Continued Care

After the doctor sees Sarah's CT scan, he immediately orders a head MRI because he sees that her CT scan was abnormal. Even though Sarah is conscious now, he wants to take another look at the happy haps in her head. Below are Sarah's MRI results:



Use your research skills to determine why the doctor ordered an MRI on top of the CT Sarah had already undergone. In addition, find out how this procedure works so you can explain it to Sarah.

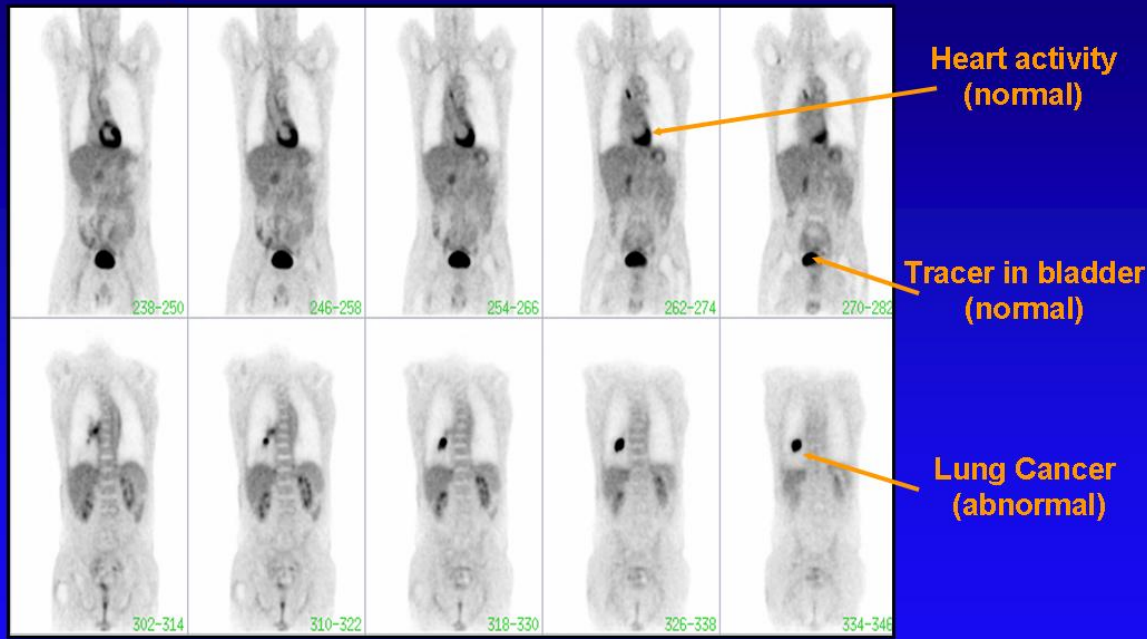
<http://www.two-views.com/MRI/What.html>

Complete Name	Why the doctor wanted an MRI (ie. how the image is formed)	Advantages of the diagnostic test	What does an MRI procedure entail for the patient?

Scenario #3: George's Growths

George is a 76-year old male, with a history of lung cancer. 5 years ago he had 1/3 of his left lung removed due to the presence of malignant tumors. Since the surgery, he has been asked to monitor his blood oxygen levels and inform his doctor if they fall below 95%. Lately, George has noticed a decline in his blood oxygen levels and returns to see his doctor. Knowing George's dark history with lung cancer, the doctor does not waste any time in ordering a chest CT. The results show a small dense nodule on his right lung. To determine whether George's lung cancer has returned, the doctor orders him to travel to Saskatoon to receive a PET scan.

PET Scan: An Example



Using your mega-awesome research skills, find out how a PET scan is helpful in determining the presence of cancer.

<http://cancergrace.org/cancer-101/2007/01/09/pet-scanning-intro/>

[http://www.hopkinsmedicine.org/healthlibrary/test_procedures/neurological/positron emission tomography pet scan 92,P07654/](http://www.hopkinsmedicine.org/healthlibrary/test_procedures/neurological/positron_emission_tomography_pet_scan_92,07654/)

Complete Name	Why the doctor wanted a PET (ie. how the image is formed)	Advantages of diagnostic test	Disadvantages of the diagnostic test

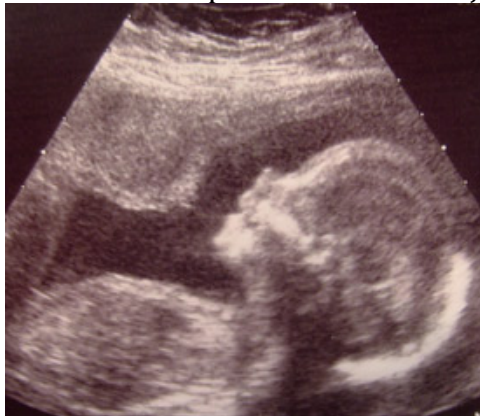Scenario #4: Baby Beats

Joni has always wanted to be a mother. Her wedding was only a few months ago, but immediately afterwards, she and her husband begun trying to have a baby. Her period was 5 days late and a home pregnancy test confirmed her excitement. To be safe, she and her husband booked an appointment with their family doctor; turns out Joni and Caleb will be parents very soon! Today, she is going to see her doctor to have her 20-week ultrasound. Joni is nervous and is unsure about what the ultrasound consists of. Use your fantastical research skills to help Joni’s anxiety by filling in the table below.

http://www.babycenter.com/0_all-about-ultrasounds_329.bc

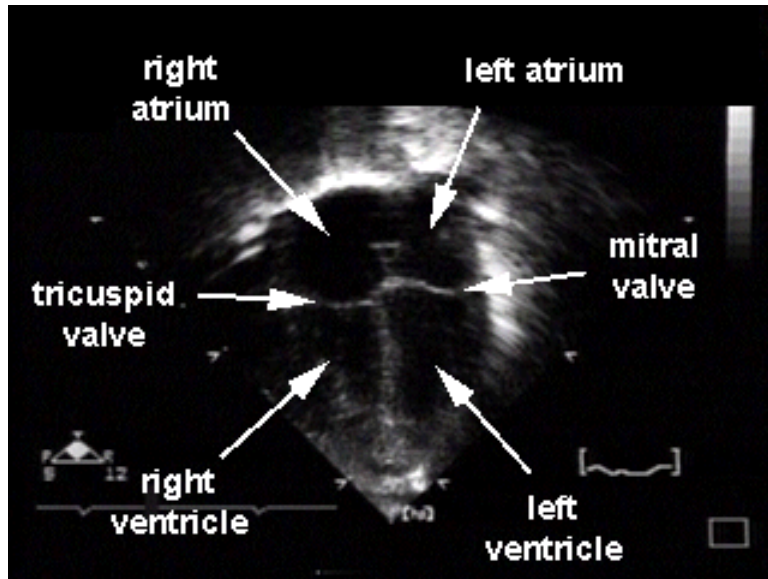
Complete Name	Why the doctor wanted an ultrasound (ie. how the image is formed)	What does an ultrasound procedure entail for the patient?

Below is a still picture taken from Joni’s ultrasound:



Scenario #5: A Healthy Heart

Jeremy is a regular 16-year-old. He is very physically active (plays volleyball, hockey and basketball) and his mom forces him to eat relatively healthy. One day, Jeremy is out shooting some hoops with his friends when suddenly he passes out. He regains consciousness very quickly, but his friends had already called Jeremy’s mom. When she showed up, Jeremy appeared to be absolutely fine and was already practicing his free throws again. However, his mom (who has been called a helicopter mom) insists on taking him to the hospital anyway. Upon completion of his check up, the doctor tells Jeremy and his mom that he thinks Jeremy suffered a mild heat stroke but thought he might have heard a slight heart murmur during Jeremy’s examination. Just to be safe, he is ordering an echocardiogram for Jeremy.



The doctor shows Jeremy the picture you see to the left. By filling out the table below, help the doctor explain to Jeremy how a picture like this will be produced of Jeremy’s heart.

<http://www.medicalradiation.com/types-of-medical-imaging/other-types-of-medical-imaging/ultrasound-imaging/>

<http://www.health.harvard.edu/diagnostic-tests/echocardiogram.htm>

Complete Name	Why the doctor wanted an echocardiogram (ie. how the image is formed)	Advantages of diagnostic test	Disadvantages of the diagnostic test

Additional Terms you may come across during your research that may be helpful to know:

Contrast agent: used to make organs or blood vessels visible on medical images. They can be given by injection into the blood stream or via tubes into internal organs. They can also be taken orally (ie. barium products).

Angiography: is an x-ray technique used in the examination of the arteries, veins and organs to diagnose and treat blockages and other blood vessel problems. During the angiogram, a catheter is inserted into a blood vessel and a contrast agent is injected to make the vessels visible. Angiograms can be performed with x-rays, CTs or MRIs.

Fluoroscopy: a specific type of x-ray imaging used when real-time examination of the patients body is required. As the x-ray beams are detected, the image is displayed on a fluorescent screen.

Mammography: a specific type of x-ray imaging that uses a low dose x-ray system specially designed for creating detailed images of the breasts known as mammograms (screening tool used to detect early breast cancer in women).

Carcinogenic: a cancer causing substance or agent